

MLS[®] Laser Therapy: A Case Study

Suzanne Plamondon, DVM, MBA,
CVA, CCRT, Diplomate ABVP

Integrative Veterinary Care &
Canine Rehabilitation, Inc.

Delray Beach, FL



Treatment of Chronic Hind Limb Lameness with Severe Paresis

Patient:

Lexi, F (s) Mixed Black Lab, 15 y, 43 pounds

History:

A seasonal snow bird client presented Lexi, a geriatric female spay mixed lab for progressive hind limb paresis. The dog was able to go for a walk around the block nine months ago and now can only go out to the back yard with assistance in ambulating.

The medical records from the referring DVM indicated a torn right anterior crutiate ligament that was toe touching lame over two years ago, which had been treated with chiropractic and laser therapy - frequency and full setting parameters unknown. The owner noticed a right head tilt at the same time. The pet has been progressively deteriorating with progressive hind limb weakness, difficulty rising and walking and periodic collapse, as well as deteriorating cognition, sight and hearing. The dog only sleeps in right lateral recumbency. The owner indicated the pet has not tolerated multiple attempts at acupuncture in the past.


Medications included 50 mg Rimadyl SID, Pepsid 20 mg SID in morning, 2 Dasaquin + MSM SID and Missing Link joint supplement on food (Marek chicken and sweet potatoes). Gabapentin 60 mg was prescribed but the owner indicated the dog acted "weird" on 60 mg so she discontinued the drug.

Exam:

Physical examination revealed an alert geriatric dog with a gentle temperament. The dog was panting, sitting, with the right hind (RH) limb folded under her and was unable to rise. She tail wagged in enthusiasm and responded to her name call and whistle indicating she was able to hear. Pupillary light reflexes (direct and consensual) were normal. Mild cataracts and lenticular sclerosis were noted bilaterally and dog's vision was good for this age. There was a notable head tilt to the right and the dog would sway its head left to right when attempting to balance to stand. Her skin had a rough hair coat and a non-painful

egg sized lipoma was noted in the left inguinal region as well as a large left diffuse infiltrated lipoma of the left auxiliary region. The dog was urinary competent and able to defecate.

On muscular-skeletal exam Lexi's right hind limb was crossed over the sagittal plane. Lexi's conformation displayed extreme lumbar kyphosis, atrophy of supra/infraspinatus and the gluteal muscles. Marketed hypertrophy of triceps and significant pain was elicited to palpation of the adductors, quadratum lumborum and the pectineous. Myofascial trigger points were detected bilaterally in the shoulders, gluteals and L2-L3 (acupoint for tendons and ligaments.) The RH limb crossed over in ridged extension under medial plane without apparent awareness to the dog and she would collapse periodically to the right side. The owner explained Lexi has been doing that for over a year since the noticeable right head tilt. The pet could right the paw after multiple attempts, take a few steps then would cross the RR over and collapse to right side again. The dog could not rise unassisted for most of the exam and ambulation attempts caused rapid weakness and fatigue.



Neurological exam revealed normal proprioception in both front limbs, significantly delayed in the left hind and absent in the right hind. The pet remained

in RH dosiflexion until manually corrected. Reflexes were hyper-reflexia in all four limbs; mild UMN in front limbs. Both patellar reflexes were highly exaggerated worse on the right versus the left rear.

MLS[®] Laser Therapy: A Case Study

Treatment of Chronic Hind Limb Lameness with Severe Paresis

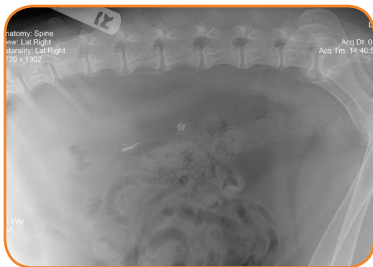
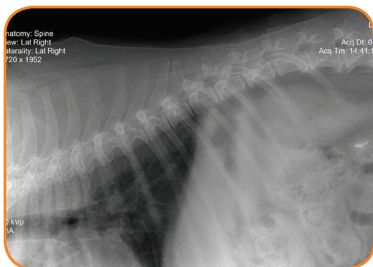
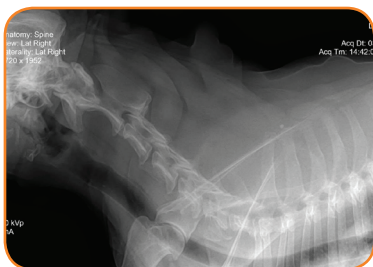Differential Diagnosis:

Ischemic lesion above foramen magnum (ischemic vs. neoplastic) to account for head tilt, UMN symptoms in all 4 limbs, lateralizing parietic lesions to the right Intervertebral disk disease (IVDD), chronic osteoarthritis, an ischemic spinal event such as fibro cartilaginous emboli (FCE) to the right side of the spinal column, hip dysplasia, spinal spondylosis, or a combination of any of the above concurrent conditions.

Diagnostic Results:

Radiographs: (From referring DVM, lateral views only)

Irregular remodeling of ventral vertebral bodies of C3-C4, a possible suspicious oval opacity, narrowed disk spaces at T4-T5-T6, mild spondylosis, severe lumbal sacral spondylosis, ventral osteoarthritis of L2-L3-L4



Treatment Options:

Laser therapy, acupuncture, neuropathic and holistic medications, hydrotherapy and physiotherapy.

Treatment Plan:

- MLS Laser Therapy treatments with concurrent acupuncture (L+A) over a 4-week period, then as needed.
- After 3 weeks of controlling centralized pain with L+A, assisted hydrotherapy and physiotherapy to improve proprioception and neurological dysfunction.
- Recommence gabapentin and consider amitriptylyne for neurological pain.

Referring DVM, MLS Laser Therapy Protocols: (Frequency and full setting protocols unknown)

Setting: Chronic Arthritis

Large Probe:

Point to Point (PTP) - 4 points along spine

PTP - 2 spots each hip

PTP - 2 spots each shoulder

Small Probe:

PTP - 4 spots each knee

Treatment:

Acupuncture needles were easily placed without resistance dry needle technique: GV 20, BL11, BL23 (L2-L3) GB 29, GB 30, GB34, BL54, BL36, BL40, BL60, KI3. Once the needles were set the MLS Therapy Laser was used directly over the needles at 8 inches away according to the following protocols.



MLS Laser Therapy Protocols:

Setting: Chronic Inflammation

Probe Used: Large

Mode: FPW

Hz: 36

Treatment Delivery: Point to Point

Points: 15

Dose: 4.01 J/cm²

Total Joules: 1203.2

Total Time per Treatment: 13 minutes 16 seconds

Phototype: White

Intensity: 100%

Treatment Area & Points: 4 points over spine (cervical through lumbar), 1 point lumbal-sacral joint, 2 points bilaterally over hips, shoulders, tarsi, stifles and quadratum lumborum muscles

Treatment Interval: Once a week for the 3 weeks due to intensity of combination treatment and weakened state of the geriatric pet. Treatment plan to commence hydrotherapy and physiotherapy at week 4.

Results: Dramatic Improvement

Lexi's response to treatment was dramatic. She fell asleep comfortably while being treated with no irritability to acupuncture needles. After laser was completed the dog got up and walked straight across living room and followed the owner into the kitchen without any knuckling. She started to slightly cross extensor her RH limb but corrected the misplacement within two seconds and even turned to the right and followed her owner back along tile floors without slipping or collapsing. Her hind conformation was notably wide based stance for balance. Her tail was up and wagging compared to low and between her legs before therapy.

Two days after the first treatment the owner indicated that Lexi had slept most of the next day (expected fatigue) then wanted to run in the evenings and attempted to jump onto the bed. The client claimed she hasn't seen this level of activity in over two years. She has been "rising and walking and barely crossing over her hind limbs". Her attitude was brighter, more alert, with improved appetite and less panting.